

Name: [Redacted] Sex: Female Height: 162.5 cm
 Patient: [Redacted] Ethnicity: White Weight: 86.0 kg
 DOB: [Redacted] Age: 69

Referring Physician: [Redacted]

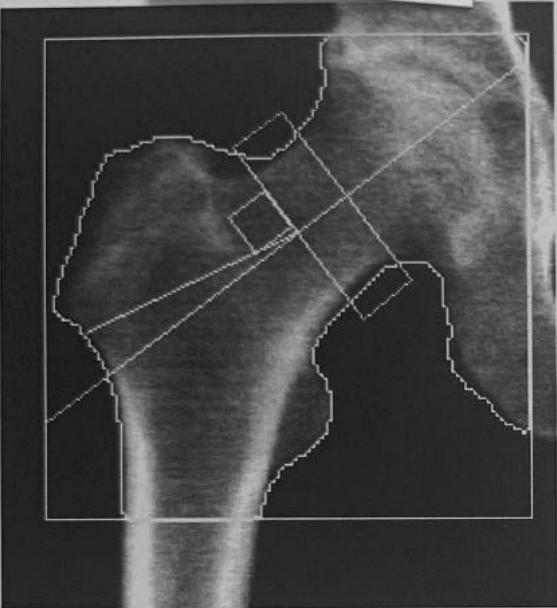


Image not for diagnostic use
 k = 1.120, d0 = 47.2
 111 x 111
 NECK: 49 x 15
 DAP: 3.2 cGy*cm²

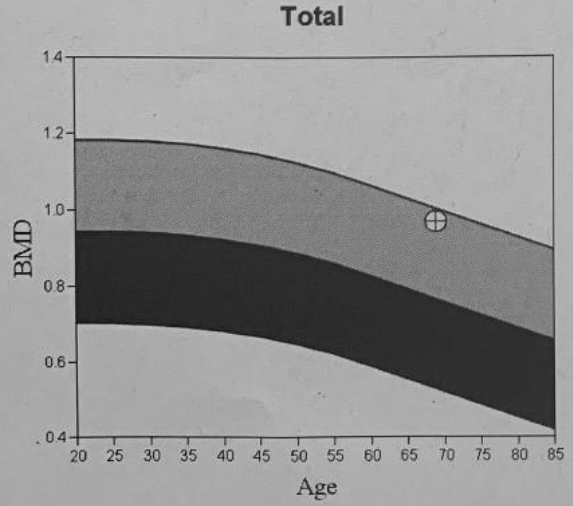
Scan Information:

Scan Date: 18 February 2021 ID: A0218210B
 Scan Type: a Right Hip
 Analysis: 18 February 2021 09:20 Version 13.4.2:3
 Hip
 Operator: [Redacted]
 Model: Discovery SL (S/N 87498)
 Comment:

DXA Results Summary:

Region	Area (cm ²)	BMC (g)	BMD (g/cm ²)	T-score	PR (%)	Z-score	AM (%)
Neck	5.49	4.59	0.836	-0.1	98	1.6	127
Troch	15.55	11.51	0.740	0.4	105	1.6	129
Inter	25.64	29.35	1.145	0.3	104	1.5	125
Total	46.68	45.44	0.973	0.3	103	1.7	127
Ward's	1.17	0.72	0.617	-1.0	84	1.5	139

Total BMD CV 1.0%, ACF = 1.037, BCF = 1.014, TH = 6.259
 WHO Classification: Normal
 Fracture Risk: Not Increased



Comment:

T-score vs. White Female; Z-score vs. White Female. Source: BMDCS/NHANES White Female.



Figure 7: Hip BMD analysis and result for Case Study 1

9.2 Case Study 2

Referral reason and clinical history

This 50 year old, white woman was referred for a follow up DXA scan to assess the change in bone mineral density after taking Letrozole for the last 4 years. The patient has had two previous assessments in 2017 when treatment was started and again in 2019 to assess a ROC. She had undergone surgical menopause via bilateral oophorectomy at the age of 45.

The most common type of breast cancer is oestrogen positive receptor breast cancer which is sensitive to changes in oestrogen therefore it is important to try and block the effect of oestrogen on the cancer by preventing stimulation of the disease. This patient is post-menopausal so oestrogen levels have already been reduced but small amounts are still present within the body. Letrozole falls into the category of medicine known as aromatase inhibitors, they work by blocking the enzyme aromatase from converting the hormone androgen into oestrogen. With the level of oestrogen at an all-time low, the risk of osteoporosis is greater.

At the time of her scan in 2017 the patient was still having regular periods and had just started Letrozole treatment. Her results indicated osteopenia however her BMD was at an expected level for her age. it was recommended that the patient start treatment in the form of a bisphosphonate, to counteract the effect Letrozole has on her bone health. She was advised to take Aledronic acid along with supplementation of calcium and Vitamin D, with treatment response being monitored using serum P1NP at baseline 6 months. Repeat DXA was advised after 2 years. Other risk factors indicated were, oral steroid therapy, low dietary intake and limited sunlight exposure.

In 2019 the patient returned for her follow up assessment. She had undergone a bilateral oophorectomy since her previous scan. Spine BMD had increased by 4.4% with no significant change at the Hip. The patient's results were still indicative of Osteopenia however the patient had only briefly taken Aledronic Acid as had commenced high dose Ibandronate as adjuvant treatment for her breast cancer. She had continued to take her calcium and Vitamin D supplements. As the previous bone treatment had prevented bone loss she did not require further bone densitometry whilst she remains on Ibandronate. Other risk factors indicated were, Letrozole, oral steroid therapy, low dietary intake and limited sunlight exposure.

Scan Acquisition and Analysis

The standard pre-scan checks were undertaken. There was no risk of pregnancy as the patient had undergone surgical menopause. There were no issues with positioning and the array scan mode was chosen as it was the mode for which the previous assessments were scanned in. Since this was a follow up scan, the compare facility was used to match the current scan as closely as possible to the previous analysis. The global ROI and bone map were already identified for both scans.

Scan Results

The results of the lumbar spine (figure 13) showed the patient have a total BMD of 0.856g/cm² giving a T-score of -1.7 which is defined as Osteopenia by the WHO classification. In 2015 the TScore was -1.4 which also placed the patient at that time in the osteopenic range. The patient has a Z-score of -1.0 with an age matched percentage of 89% which is below average for age. Since the previous scan in 2019, the rate of change shows a decrease in BMD of 2.3% (figure 14). The reference population is white female and the reference data comes from Hologic.

The BMD result for the total hip (figure 11) is 0.751g/cm²; this gave a T-score of -1.6 which is defined as Osteopenia by WHO. A Z-score of -1.1 was calculated for the patient giving them an aged matched percentage of 85%, this is below average for age. A ROC was measured for BMD between

the scans and showed a decrease of 4.2% (figure 12). The source of the reference population is white female and the reference data comes from NHANES III. VFA was required for this patient as the Z-score did not fall below 2.0% and no fractures were already known.

Clinical Outcome

The reporting clinician did not feel there was the requirement for further bisphosphonate treatment at this time to protect bone strength however suggested a repeat serum P1NP in 1 years time. If the patients P1NP is >40ug/L then they could start a once weekly alendronate treatment with a repeat referral back to metabolic bone in 18-24 months. Lifestyle advice to be given by GP along with supplementation of Calcium and Vitamin D.

The following section contained further scanning evidence but they have been removed in order to reduce file size.

The following section contained training evidence but has been removed to maintain anonymity.

Appendix 7 - Incident Reporting

Radiation Protection Protocol 9: Incident Reporting

Protocol 9 -Appendix 1

RADIATION INCIDENT		
[REDACTED]		
Date of Incident: 03.12.2021 DATIX number: Wxxxxxxx	Time of Incident: 8:30	Room Number: Scan room 1, 112-GF-16 [REDACTED]
Details of Equipment Involved		
Type of Equipment: Hologic Discovery A	Serial Number: [REDACTED]	Is the equipment still in Use? N/A
Does the equipment pose a risk? N/A.	Has the room been locked and warning notices posted? N/A.	Have service engineers been notified? N/A
Details of Person Exposed:		
Name: XXXXXXXXXXXX	Date of Birth: xx/xx/xx	Hospital Number: XX0000
Address: xxxxxxxxxxxxxxxxxxxxxxxxxxxx		
Details of Scans performed: 1. DXA of right proximal femur and lumbar spine. 2. VFA	Estimation of Dose:	
Name(s) of Staff present at time of incident:	1) xxxxxxxxxx- Scan Technician In [REDACTED]	
Name of Person Completing this form:	DC	
Details of incident		

<p>Patient had DXA scans of the hip and spine that had not been requested. The patient was attending [REDACTED] direct access service for IV zoledronate and was booked in for a VFA scan which had been authorised under the standard DA pathway at the 4th infusion visit. The direct access outcome ticket for the previous infusion had indicated that only a VFA scan was required however the scan technician also performed the DXA of spine and hip in error. The patient had been attended on CRIS by the clerical team and DXA and VFA had been entered on the system although only VFA had been requested. The scan technician had then selected the patient from the worklists and carried out the DXA scans as well as the VFA scans.</p>
<p>Action Taken</p>
<p>Who Informed? (e.g. Clinical Governance Team, RPA, RPS, Clinical Lead, Matron, engineers)</p> <p>Reported on DATIX : xxxxxxxxxxxx</p> <p>The Scan technician who acquired the incorrect imaging</p> <p>RPS Informed via the DATIX system</p> <p>Radiation Protection team informed:</p> <p>Medical Physics Report:</p> <p><i>The effective dose to this patient from the unintended spine and hip exam VFA exam has been estimated as 20 μSv (2). This dose is equivalent to around 3 days of background radiation. Public Health England describes doses of this magnitude as 'Negligible Risk' with an associated additional lifetime risk of cancer of less than 1 in 1,000,000.</i></p> <p><i>This incident, where the intended dose⁽¹⁾ of around 0.003 mSv is under 0.3 mSv and the total dose received by the patient of approximately 0.023 mSv is significantly less than 1 mSv, does not require reporting to the Care Quality Commission (CQC). The Operator involved should be reminded of their responsibilities under the Ionising Radiation (Medical Exposure) Regulations 2017 to ensure doses to patients are kept as low as reasonably practicable. Current advice from the CQC is that the operator should be asked to write a reflective statement on this incident and their learning outcomes from it.</i></p>
<p>Details of further Action Taken</p>
<p>It was verified that there had only been a request for VFA imaging and not a request for DXA imaging of hip and spine.</p> <p>The scan technician who acquired the imaging thought as DXA of the spine and hip had been entered on CRIS she had performed this and not checked the request form.</p> <p>The scan technician was reminded of the imaging requirements of the Direct Access protocol at each time point and the importance of confirming which imaging has been requested and authorised.</p>

Bibliography redacted